

- SILBERSIEPE, E., und BERGE, E. (1958): Lehrbuch der speziellen Chirurgie für Tierärzte und Studierende. 13. Aufl. Stuttgart 1958.
- STEGE, G. (1959): Penisknochen bei einigen Tierarten. Tierärztl. Umschau 14, 123—125.
- STOCKHAUS, K. (1965): Metrische Untersuchungen an Schädeln von Wölfen und Hunden. Zeitschr. zool. Syst. Evolutionsforschg. 3 (1—2), 157—258.
- TENIUS, K. (1956): Wieder zwei Wölfe in Niedersachsen erlegt! Säugetierkd. Mitt. 4, 127 f.
- WAGNER, K. (1930): Rezenten Hunderassen. Eine osteologische Untersuchung. Skrift. utgitt av det Norske Videnskaps-Akad. i Oslo. I. Mat. Nat. Klasse 1929, Nr. 9, Oslo.
- ZENETTI, P. (1934/35): Ausgrabungsergebnisse und Funde von Schretzheim-Dillingen (Oktober 1933 — Dezember 1934). Jahrb. Hist. Ver. Dillingen 47/48, 1—17.
- ZIETZSCHMANN, O., und KRÖLLING, O. (1955): Lehrbuch der Entwicklungsgeschichte der Haustiere. 2. Aufl. Berlin—Hamburg.

Anschrift der Verfasser: Prof. Dr. JOACHIM BOESSNECK und Dr. ANGELA VON DEN DRIESCH-KARPF, Institut für Paleoanatomie, Domestikationsforschung und Geschichte der Tiermedizin der Universität München, 8 München 22, Veterinärstraße 13

Regeneration and Transplantation of Antlers in Deer, Cervidae

By ZBIGNIEW JACZEWSKI

Department of Experimental Breeding of Animals, Polish Academy of Sciences, Popielno, district Pisz, Poland

Eingang des Ms. 16. 1. 1967

Introduction

In a previous paper (Z. JACZEWSKI, 1961) the literature concerning antlers has been discussed. In the meantime some new interesting works were published on this subject, which should be mentioned here.

The blood pressure in the pedicle arteries of red deer stags in various seasons of the year was measured (Z. JACZEWSKI, W. ŻUROWSKI, L. ZANIEWSKI 1962, 1965). The neogenesis of hair and skin in antlers has been described (R. E. BILLINGHAM, 1958; R. E. BILLINGHAM, R. MANGOLD, W. K. SILVERS, 1959). The regeneration of antlers in sika deer (*Cervus nippon* Temminck) has been investigated by R. J. Goss (1961). Nevertheless the conclusion of Goss, that the greatest morphogenetic potential of the pedicle is concentrated in its lateral region seems doubtful. The pedicle blood vessels run on the lateral side of the pedicle. Extirpation of the lateral half of the pedicle would be connected with serious injury to these vessels. This is perhaps a simpler explanation of Goss' results. Similar opinion was expressed by A. BUBENIK (1963) and by A. BUBENIK and R. PAVLANSKY (1965). R. J. Goss investigated the function of skin in the regeneration and growth of antlers (1964), and the role of others factors involved (1963). He examined also the regeneration of antlers in very young Virginia deer (1964 b) and was interested also in theoretical aspects of antler regeneration from the evolutionary point of view (1965).

Problems of regeneration and transplantation of antlers were investigated also by R. PAVLANSKY and A. BUBENIK (1960), A. BUBENIK (1962), A. BUBENIK (1963), A. BUBENIK and R. PAVLANSKY (1965). These authors advanced the hypothesis that growth and regeneration of antlers are regulated by special nervous centres, located perhaps in

the diencephalon. These centres would be informed by sensory nerves of the eventual injury to the antlers. Then these centres would influence by trophic nerve fibres the antlers growth. It is left to the intuition of the reader, what kind of nerve fibres exert this trophic influence. In my opinion such an influence might perhaps be exerted by vasomotor fibres. Unfortunately up till now BUBENIK and PAVLANSKY have not proved the existence of such nervous centres by classical physiological methods.

Several works concerning the biochemistry of antlers have been published. The ash, calcium and phosphorus contents of antlers have been investigated (R. BERNARD, 1963), and the histochemistry of antlers (J. A. MOLELLO, G. P. EPLING, R. DAVIS, 1963). The significance of alkaline phosphatase in antler growth was demonstrated by E. A. GRAHAM et al. (1962), and by R. E. KUHLMAN et al. (1963).

There are also new publications concerning old problems of antler growth. W. ZUROWSKI (1964) raised once more the question of the connection between lesions of legs and the asymmetry of antlers in red deer. The occurrence of antlers in Virginia deer females has been described by A. O. HAUGEN and E. W. MUSTARD (1960), and by J. C. DONALDSON and J. K. DOUTT (1959, 1965). Once more the problem of antler casting by reindeer females was raised (P. C. LENT, 1965). The influence of light on antler growth in roe deer was observed by K. EIBERLE (1965).

The present work is a direct continuation of previous investigations (Z. JACZEWSKI, 1961). It is based for the most part on further observations of red deer stags and fallow deer bucks, described in the previous paper. Nevertheless the further course of these experiments was sometimes very interesting and unexpected and deserves publication. Moreover some new experiments concerning antler regeneration in red deer stags and fallow deer bucks are described.

The experimental animals were located on a fenced farm in several not very big enclosures. Such a situation facilitated the observations.

The course of the experiments

I. Red deer stag „Turysta“

Turysta cast his successive antlers in March 1961: the right, operated antler was cast between the 16–17th, the left, normal one between the 17–18th, and the antler, grafted on the frontal bones on the 22nd. The operated antler had 5 points and weighed 1340 g, the normal one had 6 points and weighed 1670 g and the grafted antler had 3 very small points and weighed 50.5 g.

In the next year the right, operated and the left normal antlers were cast between the 25–26th of February, 1962, the grafted antler was cast between the 26–27th. Normal antler 6 points, weight 1430 g, operated one 5 points, weight 1220 g. The grafted antler was not found and its weight is unknown.

Comparison of Turysta's antler weight in successive years (g)

Year	normal	operated	grafted
1956	37	68	6.8
1957	347	355	58.70
1958	703	851	85
1959	1100	800	40
1960	1400	1150	70
1961	1670	1340	50.5
1962	1430	1220	?

Turysta died on 19th October, 1962. His last antlers are on the prepared out skull, their weight is unknown (Fig. 1 and 2). The length of these antlers, and the number of their points indicate, that they are smaller than the previous antlers. The operated antler has only 3 points, and the normal one 4, the grafted antler has none. The operated antler has no brow tine, this being also evidence of regression. The chord-

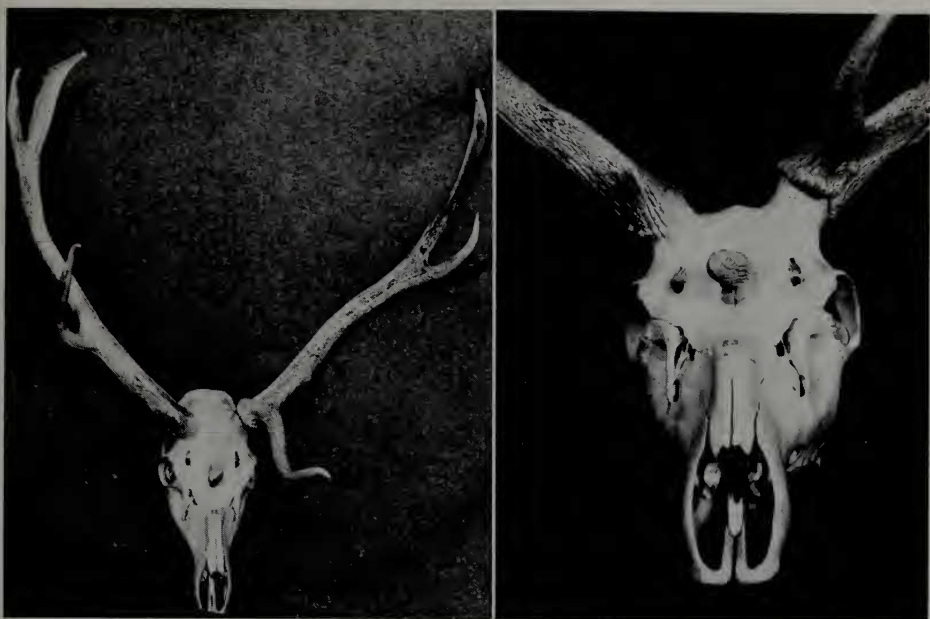


Fig. 1 (left) and Fig. 2 (right). Skull of red deer stag Turysta (Photo B. GAŁKA)

length of the last antlers in comparison to the same length of the foregoing pair is as follows: operated 68 cm—71 cm, normal 70 cm—76 cm. The last grafted antler is 5 cm long.

This comparison is somewhat inaccurate, because, as pointed out in the description, sometimes small pieces of antler tips were broken off and not found. This concerns the operated antler in 1956, 1957, the normal antler in 1959 and the grafted one in 1957. Nevertheless, it may be stated, that during three successive years after the operation the operated antler was heavier than the normal one, in spite of missing brow tine. The brow tine on the operated antler appeared first in 1959 and disappeared in the last set of antlers, which should have been cast in 1963. The weight of the grafted antler shows one peak in 1958 and a second one in 1960.

II. Red deer stag „Rączy II“

In 1960 Rączy II started the shedding of the velvet on the left normal antler on August 5, and on the right, operated one on August 6, the



Fig. 3. Skull of red deer stag Rączy (Photo Z. WDOWINSKI)

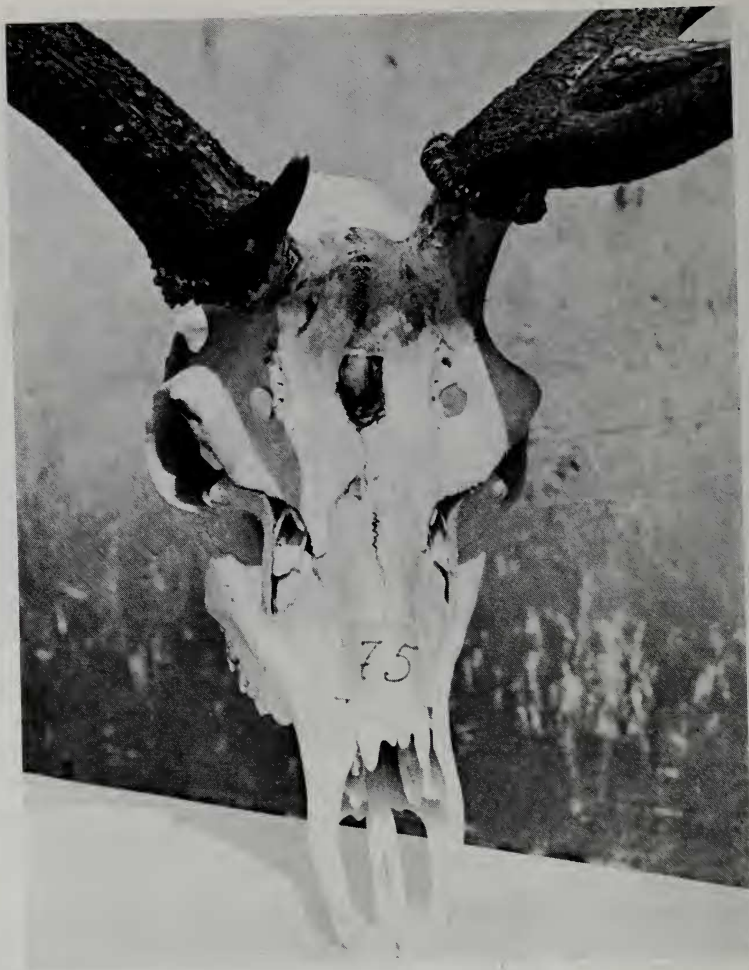

Fig. 4. Skull of red deer stag Rączy II. On the right operated antler a weak brow tine can be seen. Also a very small frontal graft is visible.
(Photo Z. Wdowski)

process ended on August 9 and on August 14, respectively. Operated antler cast March 26, 1961, 4 points, weight 810 g. Normal antler cast March 26–27, 1961, 7 points, weight 980 g.

In the next year the velvet on the normal antler was shed between the 1st and 2nd August, 1961, and on the operated one between the 4th and 8th August, 1961. During the rut, in the night between the 26th and 27th September, 1961, Rączy II broke the fence and ran away from the farm. He was shot in the forest on October 10, and his skull was prepared out (Fig. 3 and 4). The antlers on the skull are bigger than the antlers cast in March, 1961. The normal antler on the skull has 6 points and is 64 cm long (previous one 60 cm long). The operated antler on the skull has 5 points and is 67 cm long (previous one 64 cm long). On the frontal bones, in the place of grafting is an oval protuberance of the following dimensions: 3 cm, 2 cm, 0.75 cm (height).

In this experiment chiselling stimulated the regeneration for two years after the operation. The first pair of antlers was not found, but it is certain, that the operated

antler was bigger than the normal one. The successive weights of the Rączy II antlers are as follows (g):

The characteristic shape of the operated antler persisted till the death of the stag.

Year	normal	operated
1958	?	?
1959	430	470
1960	760	730
1961	980	810

III. Red deer stag „Lejek“

Lejek died on October 5, 1960, on account of a wound inflicted by another stag. On his skull is only the left, operated antler with five points, two of which are directed to the median side (Fig. 5).

The premature death of the animal made any conclusions as to the possibility of regeneration of the right antler in the next years, and the future development of the left antler impossible.

IV. Red deer stag „Jasio“

On November 15, 1960 the parietal graft was completely without velvet. This graft was cast on April 11, 1961, weight 12.14 g. Right, operated antler cast April 12–13, 1961, weight 330 g. Left operated antler cast April 13–14, 1961, weight 160 g. The frontal graft was cast as a very small scab (diameter about 1 mm) on April 17th, 1961.

On May 3rd, 1961 the length of the parietal graft was about 3 cm, of both operated antlers about 4 cm, and of the frontal graft about 0.5–1 mm. The velvet shedding on the operated antlers began on August 14, 1961. On the parietal graft the velvet shedding began on August 19, 1961, on that day both operated antlers were almost completely free of velvet.

The parietal graft and the left, operated antler were cast between the 3 and 4th April, 1962. The parietal graft was cast a little earlier, than the left operated antler. The right, operated antler was cast between April 4 and 5th, 1962. The frontal graft was torn off by hand on April 5, 1962, it held very lightly. This manipulation was performed to avoid the search for this small antler after casting. The parietal graft was not found. The weight of the remaining antlers was as follows (g): left, operated — 270, right, operated — 490, frontal graft — 1.32.



Fig. 5. Skull of red deer stag Lejek (Photo R. WOJCIECHOWSKI)



Fig. 6. Red deer stag Jasio. Picture taken on July 25th, 1962 (Photo Z. JACZEWSKI)

In the growth period 1962 unexpectedly the frontal graft began to grow very intensively. On June 10th, 1962, the approximate length of Jasio's antlers was as follows: operated right 30 cm, operated left 20 cm, parietal graft 3–4 cm, frontal graft 20 cm (Fig. 6).

On July 28, 1962, this rapidly growing frontal graft was broken (Fig. 7). The cause of this fracture is unknown, it may have been some kind of mechanical injury. This broken graft hung for a long time pendulously on the surrounding skin. This skin gradually underwent necrosis. On August 11, 1962, there remained only a very narrow strip of this skin, and the graft was torn off. Dimensions of this frontal graft: length in straight line — 302 mm, circumference near the tip — 100 mm, circumference near the base (in the small section deprived of velvet) — 92 mm, smallest circumference — 85 mm, average circumference — 90 mm. This graft was already hard, but still covered with velvet. Its weight was 266.5 g (Fig. 8). It is the largest graft thus far achieved, 97 mm longer and 180.5 g heavier than the largest graft of Turysta.

Jasio began velvet shedding on both operated antlers on August 17, 1962. This process ended on the left antler on August 22, and on the right one on August 24, 1962. From the parietal graft the velvet was shed on August 24, 1962. In the place, where the frontal graft had been, no growth could be observed.

On November 8, 1962, during capturing a part of Jasio's left antler was broken, its weight was 285 g. Parietal graft cast March 26, 1963, weight 19.5 g. Right operated antler cast March 27, 1963, weight 760 g. The remaining part of the left operated antler was torn off by hand on March 29, 1963, its weight was 162.5 g. The total weight of the left operated antler was thus 447.5 g.

In 1963 the frontal graft did not reappear. Both operated antlers grew normally. The parietal graft grew only in the first part of the growth season. Velvet shedding on both operated antlers started on August 22, 1963. Velvet shedding from the parietal graft started around September 1, 1963. Then there was a break in the observations and on September 17, 1963 it was found, that all the antlers were completely free of velvet. Parietal graft cast March 12, 1964, weight 24.9 g. Left, operated antler cast March 13, 1964, weight 447 g. Right, operated antler cast March 14, 1964, weight 834 g.

Velvet shedding in 1964 started on both operated antlers on August 19, and ended around August 27. The velvet shedding on the parietal graft occurred a little later. On October 6, 1964 a part of Jasio's left antler was broken, its weight was 468 g. Parietal graft cast March 19–20, 1965, weight 19.5 g. Both operated antlers were cast between March 20 and 21th, 1965. The right one weighed 1400 g, the left $348.5 + 468$ (broken part) = 816.5 g.

Jasio shed the velvet from the right antler almost completely on August 20, 1965. The velvet shedding from the left antler started on August 21, 1965. The velvet shedding from the parietal graft occurred later. On September 25, 1965, all three antlers were completely free of velvet.

The most important data concerning Jasio's antlers are gathered in Table 1. As



Fig. 7. Red deer stag Jasio. Picture taken on August 3rd, 1962. A broken, frontal graft, hanging on the skin and a small parietal graft are visible (Photo Z. JACZEWSKI)

seen, the time of velvet shedding changed very little from year to year. As a rule the velvet shedding from the parietal graft occurred later, than from the operated antlers. It is also interesting, that the parietal graft was mostly cast earlier, than the other antlers. It is an argument proving that the greater weight of an antler does not accelerate the casting.

Very interesting is Jasio's frontal graft. The operation performed in March, 1959, did not cause any perceptible growth neither in 1959, nor in 1960. Slight growth was noted as late as 1961. This graft, after tearing off in April 1962 weighed barely 1.32 g. In the fourth year after the operation (1962) the graft began to grow quickly and in July 1962, attained the largest size and weight of all the hitherto achieved grafts. This phenomenon is difficult to explain. There is but little probability, that the tearing off of this graft by hand could have stimulated its growth in the next season.

V. Red deer stag „Dziki“

Dziki cast his left, operated, single antler between April 26 and 27th, 1961, its weight was 150 g. In 1961 he set not only the left, operated antler with 3 points, but also



Fig. 8. Frontal graft of Jasio torn off by hand on April 5th, 1962; frontal graft of Jasio broken off on July 28th, 1962. For comparison a Polish 5 zł coin 29 mm in diameter is shown (Photo Z. WDOWINSKI)

Table 1

Red deer stag Jasie, born 1958, operated March 10, 1959

Date of velvet shedding			Date of antler casting or fracture			Weight in g		
Loa	Roa	Pg	Fg	Loa	Roa	Pg	Fg	Fg
Around 12. VIII. 1959 →			—	24.—25. IV. 1960	27.—28. IV. 1960	24.—25. IV. 1960	—	—
14.—23. VIII. 1960		16. VIII. 1960 →	?	13.—14. IV. 1961	12.—13. IV. 1961	11. IV. 1961	17. IV. 1961	?
14.—19. VIII. 1961		19. VIII. 1961 →	?	3.—4. IV. 1962	4.—5. IV. 1962	3.—4. IV. 1962	5. IV. 1962 torn off	1.32
17.—22. VIII. 1962		17.—24. VIII. 1962	—	29. III. 1963	27. III. 1963	26. III. 1963	28. VII. 1962 broken off	266.5
22. VIII. 1963 →		1. IX. 1963 →	—	13. III. 1964	14. III. 1964	12. III. 1964	—	—
19.—27. VIII. 1964		around 29. VIII. 1964 →	—	20.—21. III. 1965	20.—21. III. 1965	19.—20. III. 1965	—	—
21. VIII. 1965 →		20. VIII. 1965 →	22. VIII. 1965 →	—	—	—	—	—

Loa = left operated antler, Roa = right operated antler, Pg = parietal graft, Fg = frontal graft
 The arrows indicate, that only the date of the beginning of velvet shedding is known.

the right operated antler and the very small frontal graft, almost unperceptible in the hair.

Velvet shedding started on the left operated antler on August 14th, and ended on August 19th, 1961. On the right operated antler the velvet shedding started around August 19th, 1961. Both operated antlers were cast on April 10th, 1962. The left one had 3 points and weighed 260 g. The right one weighed 45 g, and had no branches. The very small frontal graft was not found.

In 1962 Dzik set also 3 antlers. The velvet shedding on the left antler started on August 13th, and ended on August 18th, 1962. The velvet shedding on the right antler started on August 18th and ended on August 22nd. Both operated antlers were cast on March 28, 1963. The left one had 3 points (a part of it was broken), and weighed 476 g. The right one had 2 points and weighed 136 g. Frontal graft cast March 29th, 1963, weight 2.16 g.

Velvet shedding in the next year started on the left operated antler on August 9th, 1963 and ended on August 16th. On the right operated antler the velvet shedding started on August 10th, and ended on August 17th. The velvet shedding on the frontal graft started on August 18th and did not end till after August 26th.

Left operated antler cast March 19, 1964, weight 757 g. Right one cast March 21, 1964, weight 234.5 g. The frontal graft was not found.

In 1964 the growth of the frontal graft was not observed. The velvet shedding on the left antler proceeded from August 5th to 17th, and on the right one from August 6th to 10th. Left antler cast March 14—15, 1965, weight 899 g. Right one cast March 19, weight 276 g.

Neither was the growth of the frontal graft observed in 1965. The velvet shedding on the left antler proceeded from August 9th to 21st and on the right one from August 9th to 27th. Right antler cast March 7—8, 1966, weight 599 g. Left antler cast March 9, 1966, weight 985 g.

The most important data concerning the antlers of the stag Dziki are collected in Table 2.

Essential in this experiment is, that the regeneration of the right antler occurred as late as two years after the operation. In the antler-season 1959/60 as well as in 1960/61 Dziki set and cast only a single left antler. The regeneration of the right antler began in the third year after the operation and improved from year to year. The frontal graft in this experiment was very weak. Negative results with grafts are not very important, because there are many factors, which may interfere with graft reception (mechanical injury, infection etc.).

VI. Red deer stag „Franuś“

The velvet on both Franuś' antlers began to dry up around July 11th, 1960. On the left, normal antler the velvet was shed almost completely on July 21st, 1960. On that day the shedding on the right, operated antler had just started. On July 25th, 1960, the velvet was shed completely from both beams, and remained only on both brow tines. Franuś died on August 25th, 1960.

In this case also the velvet shedding on the operated antler occurred later than on the normal one.

VII. Red deer stag „Miki“

The normal right antler was cast on March 11th, 1961. It had 5 points (brow tine, bez tine, royal tine and crown with 2 points) and weighed 900 g. The left, operated antler was cast on March 12, 1961. It had 4 points (small brow tine, royal tine and crown with 2 points) and weighed 730 g. Miki was destined for an acute experiment and sacrificed on May 22, 1961 (Z. JACZEWSKI, W. ŻUROWSKI, L. ZANIEWSKI, 1962).

VIII. Red deer stag „Jurek“

The operated, right antler was cast on March 5th, 1961. It had 4 points (brow tine, 3 points in the crown) and weighed 1161 g. The left normal antler was cast between March 5 and 6th, 1961. It had 5 points (brow tine, royal tine and 3 points in the crown) and weighed 1884 g. Jurek was destined for an acute experiment and sacrificed on May 15, 1961 (Z. JACZEWSKI, W. ŻUROWSKI, L. ZANIEWSKI, 1962).

The comparison of Jurek's antler weight before and after the operation is as follows.

As seen the operation described before (Z. JACZEWSKI, 1961) caused a decrease in antler weight.

Year	Left	Right
1959	1100	1150
1960	1750	1700
	operation	
1961	1884	1161

IX. Red deer stag „Puchatek“

Puchatek was born in the Zoological Garden in Wrocław in 1960. It was transported to Popielno on December 29, 1960. Operation was performed on March 7, 1961. On the frontal bones a homotransplantation was made from an antler of another stag, also born in 1960. On the parietal bones an autotransplantation was made from Puchatek's own right antler. Hence this operation was similar to those performed on Jasio and Dziki. The difference was, that on one side instead of an autotransplantation, a homotransplantation was made.

An analogical operation was simultaneously performed on another stag, born in 1960. It received as a homograft the left antler of Puchatek. This other stag died almost 48 hours after the operation (in the night between March 8 and 9th, 1961).

The chiselling on the right side of Puchatek's head was more extensive than on the left side, and the right frontal sinus was opened, as verified by introducing a probe. During the operation a chloralhydrate anaesthesia was applied.

In 1961 Puchatek set only one very small left, operated antler. It was cast on April 26, 1962, weight 4.8 g. In 1962 Puchatek set also only one left antler, smaller than in the previous year. This antler was torn off by hand on May 2, 1963, its weight was 1.26 g. In the next year Puchatek set also only one left antler, but distinctly bigger. Velvet shedding occurred from August 31st to September 1st, 1963. This antler was cast on April 19, 1964, weight 131 g. It cannot be excluded that a little earlier tearing off stimulated the growth.

In 1964 Puchatek set not only the left operated antler, but also the very small right operated antler. The velvet shedding on the left antler proceeded from August 16th to 22th, 1964. The velvet shedding on the right antler proceeded from August 26th, to 29th, 1964. The left operated antler cast April 17–18, 1965, weight 426 g. Right, operated antler cast April 22–23, 1965, weight 5.5 g.

Velvet shedding on both antlers in 1965 occurred from August 20th to 24th. Right operated antler cast 6–7 April, 1966, weight 6.25 g. Puchatek struck off himself the left antler on April 7th, 1966, while he was driven to another enclosure. This antler weighed 576 g. Thus, the smaller right antler was cast earlier than the bigger left one.

The most important data concerning the antlers of Puchatek are collected in Table 3. Grafting in this case was without results. In this case it is interesting, that the tearing off of the left antler in 1963 preceded the improvement of its regeneration. It is also interesting that the regeneration of the right antler commenced only in the fourth antler cycle after the operation.



Fig. 9 (left) and Fig. 10 (right). Red deer stag Fernando on February 23rd, 1965 (Photo B. GAŁKA)

X. Red deer stag „Fernando“

Fernando was born in 1963. Velvet shedding from the tips of his first antlers started on September 14th, 1964. On September 17th, 1964, during experiments consisting in establishing the dosage of succinylcholine chloride in red deer (L. ZANIEWSKI, 1966), Fernando's right antler together with the pedicle was accidentally broken, but remained hanging on the skin (it should be remembered that in the first antler cycle it is difficult to discern the line between the skin and the velvet. This antler did not fall away, but became accreted to the skull in an unnormal position (Fig. 9, 10).

This accreted, right antler was cast between April 18th and 19th, 1965, its weight was 34.5 g. Left, normal antler cast April 19/20, 1965, weight 31.5 g.

In 1965 Fernando set a normal, left antler with 3 points. At the right side in the place of the accretion a small antler with 2 points appeared. One point was directed downwards and the other, smaller one upwards. Moreover, at the site of the fracture a small, single antler regenerated (Fig. 10). Velvet shedding started on both antlers on August 19th, 1965, and ended on the left antler on August 21, 1965. On the right side, at the site of the accretion it also ended on August 21th, 1965. At the site of the fracture the small, regenerated, antler was finally deprived of velvet on August 27, 1965. The „accreted“ antler was cast between 11 and 12th April, 1966, weight 61.6 g. Left, normal antler cast April 12–13, 1966, weight 404 g. The „regenerated“ antler was cast between April 11th and 12th, 1966. It was very small and was not found (Fig. 11).

In 1966 Fernando set the left normal antler with 5 points (brow tine, royal tine and 3 points in the crown). The right „accreted“ antler first grew laterally, and afterwards bent upwards and ended in a 3-pointed crown. The beam of this antler had no points. The „regenerated“ antler was small and without points (Fig. 12, 13).

The velvet shedding on the left antler started on August 9th, 1966 and on the accreted antler on August 11th, 1966. Velvet shedding on the regenerated antler started on August 13th, 1966 and ended on August 24th. The normal and the accreted antlers were then almost completely free of velvet. The remnants of velvet remained only hanging on the crowns tips. These remnants fell off about September 20, 1966.

In this case very interesting is the spontaneous accretion of the broken pedicle and antler to another part of the skull and the ability of producing in this place an antler every year. At the old site, a small antler regenerated, in spite of the fact that, as must be assumed, this place was covered by skin from another part of the frontal

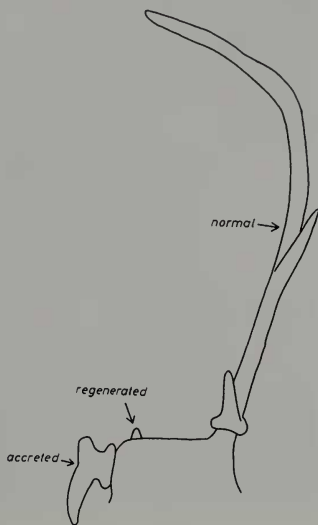


Fig. 10. Diagram of Fernando's antlers after velvet shedding in 1965

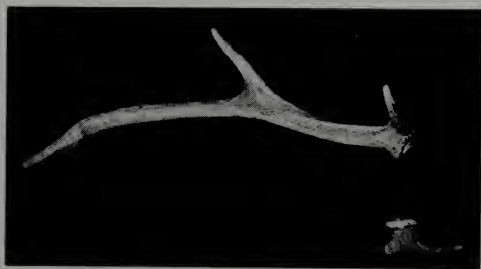

Fig. 11. Normal and accreted antlers of red deer stag Fernando cast in April 1966 (Photo B. GAŁKA)



Fig. 12. Red deer stag Fernando. Picture taken on December 9th, 1966 (Photo B. GÁŁKA)

region. Such accidents may happen in red deer in the forest and produce unnormal antlers. These anomalies cannot be hereditary and need not be designated for selective shooting.

In this case, it is also interesting, that the normal direction of growth was restored in the third antler cycle.

XI (I). Fallow deer buck „Ł-1“

„Ł-1“ died as a result of an accident on January 17, 1961. His skull was prepared out (Fig. 14). The right antler has neither burr nor pedicle and is fixed directly on the skull. Its chord-length is 31 cm. Its brow tine is very small, placed and directed unnormally. The big part of the royal tine and a part of the beam were broken off. The left normal antler is normal in shape. It has a brow tine, royal tine and a big palmation, chord-length 57 cm. On the frontal bones at the site of implantation a roughness can be seen, caused perhaps by irritation of the periosteum.

XII (II). Fallow deer buck „Ł-3“

„Ł-3“ died as a result of an accident in December 1960. His skull was prepared out (Fig. 15). The right, operated antler has no pedicle, but is placed a little further from the skull than the operated antler in fallow deer „Ł-1“. It must be assumed, that

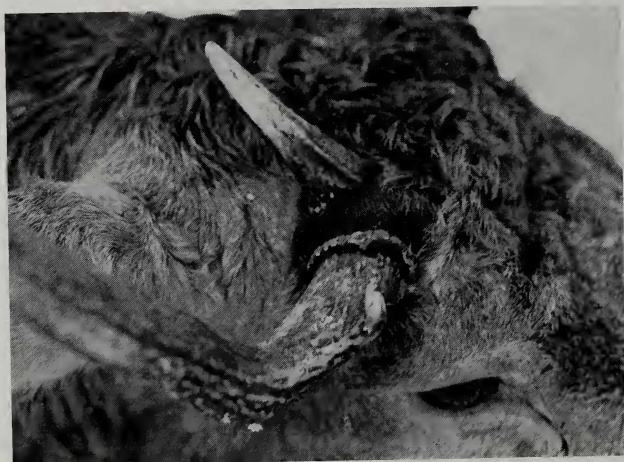

Fig. 13. Red deer stag Fernando. Picture taken on December 9th, 1966 (Photo B. GÁŁKA)

the level of amputation in fallow deer „Ł-3“ was located a little more distally, than in the fallow deer „Ł-1“. The operated antler of „Ł-3“ has a brow tine and a very small burr. The beams of both his antlers end bluntly as a result of injuries during transportation. The transport took place on July 10th, 1960, and then the antlers were in the stage of growth and the tips of their beams were susceptible to mechanical injury. The right beam is 28 cm, the right

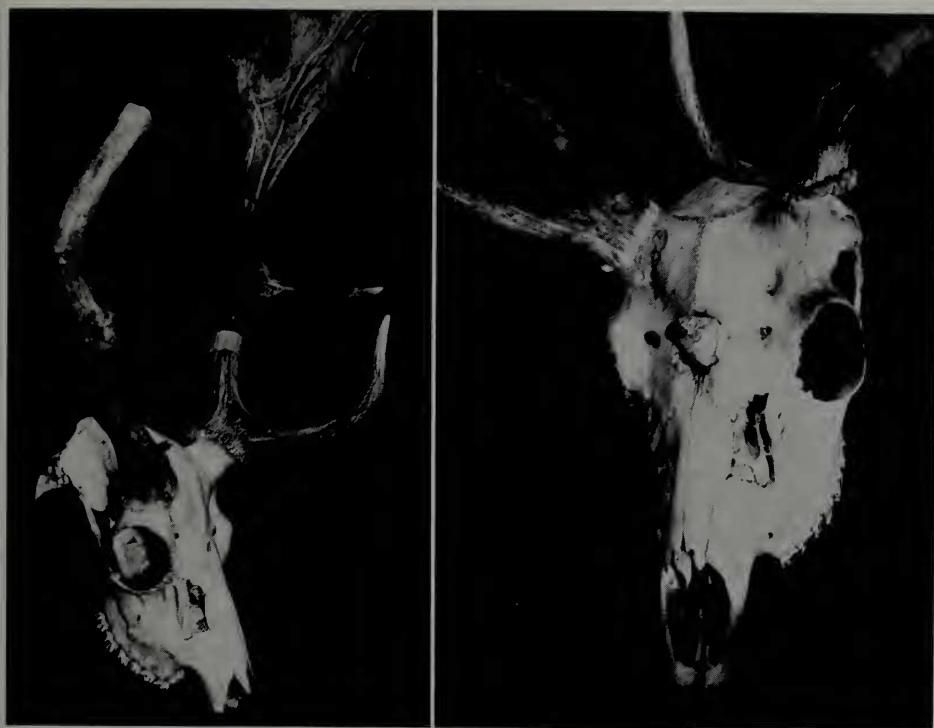

Fig. 14 (left). Skull of fallow deer buck „Ł-1“ — Fig. 15 (right). Skull of fallow deer buck „Ł-3“ (Photos B. GAŁKA)

brow tine 10.5 cm long. The left, normal antler has a beam 24 cm and a brow tine 12 cm in length. The antler grafted on the frontal bones is 3 cm long.

In this case the occurrence of the brow tine on the operated antler is interesting. The brow tine was present every year on the operated antler, with the exception of course of the first antler cycle.

XIII (III). Fallow deer buck „Ł-5“

„Ł-5“ was born in the spring of 1959. He was transported to Popielno from the Łódź-Zoo on July 10th, 1960. The experimental operation was performed on July 18th, 1960. It proceeded according to the same plan as in the red deer stags Jasio and Dziki. Both antlers were chiselled off and grafted, one on the frontal, and the other on the parietal bones. The left antler was chiselled off as near the skull as possible, and the right one about 1 cm above the skull. Besides, on the left side a narrow opening was made into the frontal sinus. This opening was on the medial side of the surface of chiselling.

The animal bore well the operation. The parietal graft fell off on July 25th, 1960. The frontal graft fell off on August 1st, 1960. On the left side, on the site of chiselling the beginning of growth could be noticed on August 2nd 1960. On the right side, and in the places of grafting growth could not be observed. On September 12th, 1960, the left operated antler was about 2 cm long. On September 15th, its length reached about 4 cm, and on September 19th about 6–7 cm. On October 4th, 1960, the left operated antler was about 10–12 cm long and was covered with pink skin with short and not

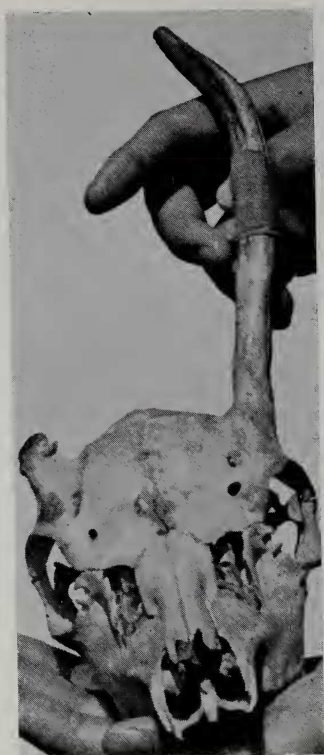

Fig. 16. Skull of fallow deer buck „Ł-5“ (Photo R. WOJCIECHOWSKI)

too abundant hair. On October 20th, the left antler was covered with abundant, thick hair and was about 18 cm long. Velvet shedding took place from October 25th to 29th, 1960. On the right side the chiselled surface remained unchanged all the time. In the places of grafting also no growth could be observed.

„Ł-5“ died as a result of an accident on January 17, 1961. His skull was prepared out (Fig. 16.). In the places of grafting small rough areas caused by irritation of the periosteum are visible. At the site of amputation of the right antler there is no growth at all, the chiselled surface is about 1.5 cm from the skull. Around this surface there are small rough patches, caused probably by irritation of the periosteum. Only the left operated antler has regenerated well, its length is 18 cm. On the medial side of this antler the course of the perieto-frontal suture is changed and complicated. This is probably due to the healing of the opening into the frontal sinus.

This experiment is interesting, because the chiselling 1 cm above the skull stopped the regeneration of the antler, but deeper chiselling on the level of the skull did not. This also requires further investigation.

Discussion

It can be assumed, that there are differences in the regenerative abilities of antlers in different species of Cervidae. A. BUBENIK and R. PAVLANSKY in their paper did write (1965, p. 299) “In case of deep injury to the pedicle base the influence of such a trauma is also transferred over to the opposite pedicle and to both the frontal bones, which start to produce exostoses.” This opinion may be correct in relation to roe deer buck, but generalization to other species seems as yet unfounded.

A. BUBENIK and R. PAVLANSKY advanced in their works the hypothesis, that the growth, development and regeneration of antlers is under the control of special nerve centres. „Information about the trauma to a definite zone of the antler is sent over by the sensory pathways into the trophic nerve centers and the trophic response is signalled along efferent nerve fibers“ (1965, p. 300). It is not easy to imagine what kind of efferent nerve fibres were meant by the Czechoslovakian authors. The only hitherto known efferent nerve fibres present in antlers are the vasomotor ones. The vasomotor regulation in antlers is as yet but little explored (Z. JACZEWSKI, W. ZUROWSKI, L. ZANIEWSKI, 1962, 1965).

In one of my works (Z. JACZEWSKI, 1955) I have advanced the theory, that the appearance of antlers in the course of evolution and their phylogenetic development are connected with regeneration. This theory was further developed in one of my further works (Z. JACZEWSKI, 1961). This theory has been later developed by a brilliant argumentation in the papers of R. J. Goss (1964, 1965). It is only a pity, that R. J. Goss did not mention, that this theory, in a certainly less perfect form, had been advanced before him.

The statement of R. J. Goss (1961, p.350), that the greatest morphogenetic poten-

Table 2

Red deer stag Dziki, born 1958, operated May 25, 1959

Date of velvet shedding			Date of antler casting or fracture			Weight in g		
Loa	Roa	Fg	Loa	Roa	Fg	Loa	Roa	Fg
?	—	—	27.—28. IV. 1960	—	—	?	—	—
16.—24. VIII. 1960	—	—	26.—27. IV. 1961	—	—	150	—	—
14.—19. VIII. 1961	19. VIII. 1961 →	?	10. IV. 1962	10. IV. 1962	?	260	45	?
13.—18. VIII. 1962	18.—22. VIII. 1962	?	28. III. 1963	28. III. 1963	29. III. 1963	476	136	2.16
9.—16. VIII. 1963	10.—17. VIII. 1963	18. VIII. 1963 →	19. III. 1964	21. III. 1964	?	757	234.5	?
5.—17. VIII. 1964	6.—10. VIII. 1964	—	14.—15. III. 1965	19. III. 1965	—	899	276	—
9.—21. VIII. 1965	9.—27. VIII. 1965	—	9. III. 1966	7.—8. III. 1966	—	985	599	—

Loa = left operated antler, Roa = right operated antler, Fg = frontal graft

The arrows indicate that only the date of the beginning of velvet shedding is known

tial of the pedicle is concentrated in its lateral region seems doubtful. His results can be explained in a simpler way by injury of the blood vessels running on the lateral side of the pedicle. A similar opinion on this problem was expressed also by A. BUBENIK (1963) and by A. BUBENIK and R. PAVLANSKY (1965). However, it should be mentioned, that ligation of the pedicle blood vessels did not check antler growth completely (Z. JACZEWSKI, L. ZANIEWSKI, W. ŻUROWSKI, 1965).

It may be concluded from the experiments described above, that the chiselling off of an antler can sometimes stop its regeneration for a few years, but after a time it starts again. For instance, the red deer stag Dziki during two years after the operation set only the left antler. The regeneration of his right antler started but in the third antler cycle. The size of this right antler increased from year to year and its regeneration gradually improved (Table 2). A similar phenomenon of a few years delayed regeneration occurred in the red deer stag Puchatek. This stag (Table 3) set for 3 successive antler cycles after the operation only the left antler. The right antler appeared in the fourth cycle after the operation. Judging from these results, some ex-

Table 3

Red deer stag Puchatek, born 1960, operated March 7, 1961

Date of velvet shedding		Date of antler casting		Weight in g	
Loa	Roa	Loa	Roa	Loa	Roa
?	—	26. IV. 1962	—	4.8	—
?	—	2. V. 1963 torn off	—	1.26	—
31. VIII.—1. IX. 1963	—	19. IV. 1964	—	131	—
16.—22. VIII. 1964	26.—29. VIII. 1964	17.—18. IV. 1965	22.—23. IV. 1965	426	5.5
20.—24. VIII. 1965		7. IV. 1966	6.—7. IV. 1966	576	6.25

Loa = left operated antler, Roa = right operated antler

periments of Goss et al. (1964) are rather unconvincing, because he conducted his observations only for one year after the operation, and only in one case for 3 years. To prove the complete abolishment of antler regeneration the observations should be conducted much longer, at least 4 years.

The problem of asynchronical velvet shedding caused by the chiselling off of pedicles is discussed in the works of R. J. Goss (1961), A. BUBENIK, R. PAVLANSKY (1965) and Z. JACZEWSKI (1961). J. R. Goss described (1961) one very interesting variant of pedicle amputation (sika deer 38). This amputation was made about one week after the old antlers had been shed — or in other words in the beginning of the growth period. This amputation caused a several weeks difference in the velvet shedding between the normal and the operated antler. In the stag Dziki, described above, the right antler was perhaps damaged more severely, its regeneration was weaker than that of the left antler. The velvet shedding on this right antler occurred as a rule a little later than on the left one. It may be presumed on the basis of this very scanty material, that there are differences in the time of velvet shedding not only between normal and operated antlers, but also between both operated antlers, in dependence on the degree of pedicle damage.

Such relations cannot be observed in respect to the time of antler casting. As seen from the tables and from the description of experiments, sometimes the more damaged, weaker antler was cast earlier than the less damaged, heavier one (e. g. DZIKI in 1966 and PUCHATEK in 1966). Jasio cast his parietal, small graft mostly earlier than the bigger operated antlers.

Stimulation of the left antler growth after the operation was observed in the red deer stag Lejek. In the first antler cycle after the operation Lejek set the left antler with 2 points, and in the second cycle with 5 points. The operated antlers cast by stag Rączy II in the two years after the operation (1958 und 1959) were heavier than the normal antlers cast on the control side. Similarly, the operated antlers cast by stag Turysta were during 3 successive years after the operation heavier than the normal antlers cast on the control side. Stimulation of antler growth after the amputation of the pedicle was described also by A. BUBENIK and R. PAVLANSKY (1955, 1965).

The modification of the red deer antler shape caused by operation persisted mostly over the entire time of observations. The operated antlers increased from year to year in size, produced more points, but the general character of their changed form

remained. This phenomenon was most pronounced in the antlers of Rączy II, Jasio, Dżiki and Puchatek.

The regeneration of the operated antler of fallow deer „Ł-1“ was very weak during the 3 successive years after the operation. Afterwards the regeneration improved, but always the operated antler was much weaker than the normal one. The operated antler of the fallow deer „Ł-3“ during 2 successive years after the operation was heavier than the normal one. Moreover, this operated antler, beginning with the second antler cycle, had a normal brow tine. It is difficult to answer, if this difference in regeneration between the fallow deer „Ł-1“ and „Ł-3“ is caused by a difference in the pedicle amputation level. The experiment with fallow deer „Ł-5“ complicated the problem of antler regeneration in fallow deer still more. In fallow deer „Ł-5“ the chiselling on one side was deeper and an opening was made into the frontal sinus. Nevertheless, on that side regeneration ensued. On the other side the pedicle was amputated about 1.5 cm above the skull, but regeneration was checked. These facts require further investigation.

Interesting and also difficult to explain is the course of the frontal graft in red deer stag Jasio. In the first year after the operation it was impossible to observe any perceptible growth at the site of frontal transplantation. In the second and in the third years after the operation a very small growth did occur in that place. But in the fourth year after the operation the frontal graft of Jasio attained the largest size and weight of all the hitherto grafted antlers. This fact can serve as an evidence how little is known about the factors regulating antler growth.

In two cases (Jasio — frontal graft, Puchatek — left operated antler) small antlers were torn off by hand just before casting. This manipulation was performed only to avoid searching for small antlers on the area of the enclosures. In both cases after such interference a great improvement of antler growth followed. This also needs further investigation.

In the case of red deer Fernando the broken antler with the pedicle became accreted to another part of the skull. This new site in the next years began to produce antlers. This phenomenon is similar to the grafting, described above and to the experiment of R. J. Goss, in which the pedicle was grafted on the ear (1964). The „accreted“ antler of Fernando began to grow in normal direction in the third antler cycle. Independently, at the site of fracture a weak regeneration ensued. This is interesting, because, as must be assumed this site was covered by skin from another part of the skull. Such accidents may occur in the forest and perhaps should not be designated for selective shooting, because such anomalies should not be hereditary.

Résumé

Dix cerfs (*Cervus elaphus* L.) et trois daims (*Cervus dama* L.) ont été soumis à des observations suivies. Une partie des observations décrites constituent la continuation immédiate des expériences mentionnées précédemment (Z. JACZEWSKI, 1961). Il a été établi dans les observations présentes que la régénération de l'excroissance peut être arrêtée pendant les trois cycles consécutifs à l'opération, et que l'excroissance ne peut être régénérée avant le quatrième cycle post-opérationnel. Il arrive aussi que l'opération qui consiste à entailler la base stimule le développement de l'excroissance, qui devient plus grande et plus lourde que l'excroissance de contrôle. Cette stimulation peut même affecter les trois cycles post-opérationnels consécutifs. Dans le cas de l'un des daims, l'entaillage au ciseau à 1,5 cm au-dessus du crâne arrêta la régénération de l'excroissance au cours de l'année suivante.

On a pu obtenir chez l'un des cerfs au cours du quatrième cycle post-opérationnel une greffe frontale, d'une longueur de 302 mm et pesant 266,5 g. Il est intéressant qu'au cours du premier cycle post-opérationnel aucun signe de croissance ne se faisait remarquer à cet endroit, et la greffe apparut d'une manière plus visible seulement au cours du troisième cycle post-opérationnel. Dans un des cas observés, une excroissance cassée avec une partie de sa base repoussa à un autre endroit du crâne.

Zusammenfassung

Beobachtungen wurden durchgeführt an 10 Rothirschen (*Cervus elaphus* L.) und 3 Damhirschen (*Cervus dama* L.). Ein Teil der beschriebenen Beobachtungen bildet eine unmittelbare Fortsetzung früher besprochener Experimente (Z. JACZEWSKI, 1961). Bei den gegenwärtigen Beobachtungen wurde festgestellt, daß zuweilen die Regeneration des Geweihes während drei aufeinander folgenden Zyklen gehemmt sein kann und das Geweih erst im vierten postoperativen Zyklus regenerieren kann. Es kommt auch vor, daß das Ausmeißeln des Rosenstocks das Wachstum des Geweihes stimuliert und dieses größer und schwerer ausgebildet wird als ein entsprechendes Kontrollgeweih. Solche Stimulierung kann sich selbst auf drei aufeinander folgende postoperative Zyklen erstrecken. In einem Fall hat beim Damhirsch das Abmeißeln des Geweihes etwa 1,5 cm oberhalb des Schädels die Regeneration des Geweihes im nachfolgenden Jahr gehemmt.

Bei einem Rothirsch ist es gelungen, im vierten postoperativen Zyklus ein Stirnbeintransplantat zu erhalten, das 302 mm lang und 266,5 g schwer war. Es ist bemerkenswert, daß hier an dieser Stelle im ersten postoperativen Zyklus überhaupt kein Wachstum zu bemerken war und ein etwas deutlicheres Wachstum erst im dritten postoperativen Zyklus auftrat.

In einem Fall ist spontan ein mit einem Teil des Rosenstocks abgebrochenes Geweih an einer etwas verschobenen Stelle des Schädels angewachsen.

Literature

- BERNARD, R. (1963): Specific gravity, ash, calcium and phosphorus content of antlers of Cervidae. *Naturalist, Canad.*, **90** (12), 310—322.
- BILLINGHAM, R. E. (1958): A reconsideration of the Phenomenon of Hair Neogenesis, with Particular Reference to the Healing of Cutaneous Wounds in Adult Mammals. *The Biology of Hair Growth*. Academic Press. New York, 451—468.
- BILLINGHAM, R. E., MANGOLD, R., and SILVERS, W. K. (1959): The neogenesis of skin in the antlers of deer. *Annals N. Y. Acad. Sci.* **83**, 491—498.
- BUBENIK, A. B. (1962): Geweihmorphogenese im Lichte der neurohumoralen Forschung. *Symposium theriologicum. Praha*, 59—66.
- (1963): Die Einstangengeweihe. *Zeitschrift f. Jagdwissenschaft* **9** (1), 6—14.
- BUBENIK, A. B., and PAVLANSKY, R. (1965): Trophic Responses to Trauma in Growing Antlers. *Journ. Experim. Zool., Philadelphia*, **159** (3), 289—302.
- DONALDSON, J. C., and DOUTT, J. K. (1965): Antlers in Female White-tailed Deer: a 4-year Study. *J. Wildl. Management*, **1965**, **29** (4), 699—705.
- DOUTT, J. K., and DONALDSON, J. C. (1959): An antlered doe with possible masculinizing tumor. *J. Mammal.* **40** (2), 230—236.
- EIBERLE, K. (1965): Über den Einfluß der Sonnenscheindauer auf die Gehörn-Entwicklung beim Rehwild. *Schweiz. Z. Forstwesen*, **116** (1), 60—64.
- Goss, R. J. (1961): Experimental Investigations of Morphogenesis in the Growing Antler. *J. Embryol. exp. Morph.* **9** (2), 342—354.
- (1963): The deciduous Nature of Deer Antlers. Mechanisms of Hard Tissue Destruction, Publication No. 75 of the American Association for the Advancement of Science, Washington, 339—369.
- (1964): The role of skin in antler regeneration. *Advances in Biology of Skin*. vol. V. Pergamon Press. 194—207.
- (1965): Mammalian Regeneration and its phylogenetic relationships. *Regeneration in Animals and Related Problems*. North-Holl. Publ. Co., Amsterdam, 33—38.
- Goss, R. J., SEVERINGHAUS, C. W., and FREE, S. (1964): Tissue relationships in the development of pedicles and antlers in the Virginia deer. *J. Mammal.* **45** (1), 61—68.
- GRAHAM, E. A., RAINEY, R. KUHLMAN, R. E., HOUGHTON, E. H., and MOYER, C. A. (1962): Biochemical Investigations of Deer Antler Growth. Part. I. Alterations of Deer Blood Chemistry Resulting from Antlerogenesis. *J. Bone and Joint Surg.*, **44-A** (3), 482—488.
- HAUGEN, A. O., and MUSTARD, E. W. (1960): Velvet-antlered pregnant White-tailed doe. *J. Mammal.* **41** (4), 521—523.
- JACZEWSKI, Z. (1955): Regeneration of antlers in Red deer, *Cervus elaphus* L. *Bull. Acad. Polon. Sci.*, **1955**, **3**, 273—278.
- (1961): Observations on the Regeneration and Transplantation of Antlers in Deer, Cervidae. *Folia Biologica* **9** (1), 47—99.
- JACZEWSKI, Z., ZANIEWSKI, L., and ŻUROWSKI, W. (1965): Observations on the circulation in the pedicle arteries of Red deer (*Cervus elaphus* L.). *Transactions of the VIth Congress International Union of Game Biologists, London 1965*, 145—155.
- JACZEWSKI, Z., ŻUROWSKI, W., and ZANIEWSKI, L. (1962): Regulation of blood pressure in the

- growing antlers of Red deer (*Cervus elaphus* L.). *Supplemento alle Ricerche di Zoologica applicata alla Caccia*. Bologna, 4, 115—139.
- KUHLMAN, R. E., RAINEY, R., and O'NEILL, R. (1963): Biochemical Investigations of deer Antler Growth. Part II. Quantitative Microchemical Changes Associated with Antler Bone Formation. *J. Bone and Joint Surg.*, 45-A (2), 345—350.
- LENT, P. C. (1965): Observations on antler shedding by female Barren-ground caribou. *Canad. J. Zool.*, 43 (3), 553—558.
- MOLELLO, J. A., EPLING, G. P., and DAVIS, R. (1963): Histochemistry of the deer antler. *Am. J. Vet. Res.*, 24 (100), 573—579.
- PAVLANSKY, R., and BUBENIK, A. (1955): Von welchem Gewebe geht der eigentliche Reiz zur Geweihentwicklung aus? I. Mitteilung: Ein Versuch der Transplantation eines Geweihzapfens bei einem Damspießfer, *Dama dama dama* (Linné, 1758). *Säugetierkundl. Mitt. Stuttgart*, 3, 49—53.
- and — (1960): Von welchem Gewebe geht der eigentliche Reiz zur Geweihentwicklung aus? IV. Mitteilung: Versuche mit Auto- und Homotransplantation des Geweihzapfens. *Säugetierkundl. Mitt. Stuttgart*, 8, 32—37.
- ZANIEWSKI, L. (1966): Zdalne unieruchamianie zwierząt nieudomowionych chlorkiem sukcyntylocholiny z zastowaniem samoczynnej strzykawki. *Biul. III Zjazdu Pol. Tow. Nauk Weter.*, Lublin, 106.
- ZUROWSKI, W. (1964): Wpływ okaleczeń na anormalny rozwój poroża u jeleniowatych. *Biul. Zakadu Hodowli Dośw. Zwierząt PAN*, 4, 121—126.

Authors's address: Dr. ZBIGNIEW JACZEWSKI, Department of Experimental Breeding of Animals, Polish Academy of Sciences, Popielno, p-ta Wejsung, district Pisz, Polen

Zur Kenntnis des 24-Stunden-Rhythmus von *Spalax leucodon* Nordmann, 1840

Von I. SAVIĆ und M. MIKES

Eingang des Ms. 10. 12. 1966

Da *Spalax* ein blindes, unterirdisch lebendes Tier ist, ist die Frage nach seiner nyctohemeralen Aktivität in Bezug auf Tag- und Nacht-Periodizität (Licht, Temperatur, Feuchtigkeit, Luftdruck u. a.) besonders interessant. Die bisherigen Kenntnisse über diesen Rhythmus von *Spalax leucodon* sind recht mangelhaft, hauptsächlich descriptiv und widersprechen einander oft.

SAVIĆ (1965) berichtete über Befunde zum 24-Stunden-Rhythmus nach 48stündigen Beobachtungen an mehreren Tierserien unter Laborbedingungen. Abb. 1 erweist, obwohl analytisch gesehen die gewonnenen Ergebnisse eine polyphasische Aktivität zeigen, eine Periode größter Aktivität zwischen 11 und 16 Uhr und eine weniger ausgeprägte in der Nacht zwischen 24 und 3 Uhr. Außerdem wurden auch Unterschiede in der nyctohemeralen Aktivität in den verschiedenen Jahreszeiten festgestellt.

Auch die Befunde an einem adulten ♂, das mit einer Vorrichtung zum Registrieren der Nahrungsaufnahme 7 Tage lang im Freien beobachtet wurde, weisen auf gewisse Perioden stärkerer Aktivität hin.

Ähnliche Ergebnisse in einem künstlichen Gangsystem brachte die Beobachtung durch 7 Tage eines adulten ♀, das ebenfalls mit einer registrierenden Vorrichtung versehen war (Abb. 2, SAVIĆ, 1966).

Diese Ergebnisse von Beobachtungen im Labor wurden durch solche in der Natur ergänzt. Es sei hier berichtet über die nyctohemerale Aktivität einer Population von